

## Fiber Projections of the Superior Colliculus in the Cat<sup>1</sup>

JOSEPH ALTMAN<sup>2</sup> AND MALCOLM B. CARPENTER

*Department of Anatomy, College of Physicians and Surgeons,  
Columbia University, New York, New York*

In submammalian vertebrates the optic tectum, a structure homologous with the mammalian superior colliculus, is the primary way-station of the fibers of the optic tract. As such, it is assumed to be of central significance in the coordination of visually-guided behavior (Huber and Crosby, '33; Ariëns Kappers, Huber and Crosby, '36). Ascending the evolutionary scale, the superior colliculus of mammals receives fewer and fewer fibers from the optic tract, as an increasing proportion of these fibers terminate in the lateral geniculate nucleus (Polyak, '57). In spite of this apparent comparative decline, the size and complexity of the mammalian superior colliculus (Huber and Crosby, '43) suggests that it is by no means a vestigial structure of little functional importance.

The fiber projections of the superior colliculus have been investigated by means of several staining techniques (e.g., Golgi, Weigert, Marchi) in a variety of mammalian species, including man (Tsai, '25, in opossum; Held, 1890, 1892, 1893, Papez and Freeman, '30, in rat; Szentágothai-Schimert, '41, in mouse; Cajal, 1896, Muenzer and Wiener, '02, Lewandowsky, '04, De Lange, '10, Nishikawa, '23, in rabbit; Held, 1890, 1892, 1893, Bechterew, 1897, Tschermak, 1898, Redlich, 1899, Probst, 1900, Collier and Buzzard, '01, Crosby and Henderson, '48, in monkey; and Held, 1890, 1892, 1893, Bechterew, 1897, Collier and Buzzard, '01, Tsuchida, '06, in man). Most of these investigators were concerned largely, or exclusively, with the descending fiber projections of the superior colliculus, and their data indicate numerous discrepancies. The present study was undertaken in an attempt to determine both the descending and ascending projections of the superior colliculus in the cat by means of

the Nauta-Gygax technique, following localized stereotaxic lesions in the superior colliculus.

### MATERIAL AND METHODS

Twenty-four adult cats were used in this study. The animals were anesthetized intravenously with Nembutal, and surgery was performed under aseptic conditions. Attempts were made to produce unilateral stereotaxic lesions in the right superior colliculus. Stereotaxic coordinates were determined from formalin fixed heads with brains *in situ* (Carpenter and Whittier, '52). A modified Labtronics instrument was used, and the electrodes were introduced, in the majority of cases, vertically in parasagittal planes (traversing the lateral gyrus of the cortex). In two animals the electrodes were inserted at angles, penetrating the occipital and frontal lobes, respectively. In general, 8 electrode placements in the superior colliculus were attempted in each animal. Spatially, these placements were at the corners of a 1-mm cube. Lesions were produced by direct current of 400 volts and 3 ma, timed electrically and allowed to pass for 10 seconds.

All animals were sacrificed, after a survival period of 14 days, by perfusion with 500 ml of 10% neutral formalin, injected into the left ventricle of the heart. Brains and spinal cords were removed *in toto* and further fixed in 10% neutral formalin. Brains were sectioned in blocks 1-2 mm thick perpendicular to the axis of the brain stem, while blocks of spinal cord were cut transversely. Selected blocks of

<sup>1</sup> Supported by research grant B-1538c from the Institute of Neurological Diseases and Blindness of the National Institutes of Health, Bethesda 14, Maryland.

<sup>2</sup> Postdoctoral trainee in Neuroanatomy supported by grant 2B-5242 from the Institute of Neurological Diseases and Blindness.

brain and spinal cord were cut serially at 25  $\mu$  on a freezing microtome, and every section was saved. Selected sections at all representative levels of the neuraxis were stained individually according to the Laidlaw modification of the Nauta-Gygax method ('54). In all animals multiple frozen sections through the superior colliculus were stained with cresyl violet in order to evaluate more precisely the location and extent of the lesions.

## OBSERVATIONS

### *Lesions*

In 19 of the 24 cats lesions were fairly well localized in the right superior colliculus, though they differed in size, configuration and disposition within this structure. Of these 19 animals, 12 were selected for study of efferent fiber projections. In some of these animals, other structures also were destroyed, in part, by the lesions; these structures, in different animals, included (a) the mesencephalic tegmentum (not including the red nucleus), (b) the periaqueductal gray, (c) the pretectum, and (d) the habenular nuclei. In spite of this variability in the lesions produced, most features of the resulting degeneration were remarkably constant.

### *Degeneration at the level of the superior colliculus*

Irrespective of the size and exact location of the collicular lesions, axonal and preterminal degeneration usually was absent from the most superficial layer of the superior colliculus, the *stratum zonale*. Degenerated fibers were seen to reach the surface of the colliculus only at two points: (1) its lateral margin, at the junction of the superior colliculus and its brachium, and (2) its medial margin, dorsal to the commissure of the superior colliculus. Fibers in both of these locations probably belong to the brachium of the superior colliculus, (cf., discussion and diagrams of Polyak, '57, pp. 306-307; and Jasper and Ajmone-Marsan, '54), though the medially located fibers are not generally regarded as part of this structure. Very few degenerated fibers were present in the next layer, the *stratum griseum*

*superficiale*, except in regions immediately adjacent to the lesion and thus directly affected by the coagulating current. In all animals numerous degenerated fibers were seen in all underlying layers, but were particularly numerous in the intermediate and deep fibrous layers (*stratum album mediale* and *stratum profundum*). Many of the degenerated fibers within the superior colliculus were found to pass haphazardly in all directions; some degenerated fibers arborized around the larger cells of the deeper layers. Efferent fibers were organized into distinct bands or tracts. The principal tectofugal fiber projections of the superior colliculus appeared to pass laterally. Fibers taking this lateral course were observed to divide into: (1) a lateral ascending division (mainly tectothalamic), (2) a lateral descending division (tectopontine) and (3) an intermediate diffuse group of fibers (tectoreticular). A smaller, medially placed fiber projection appeared to form: (1) a medial ascending division (mainly tectothalamic), (2) a small but definite commissural fiber bundle, and (3) a descending group of fibers which passed ventrally along the border of the periaqueductal gray to form the predorsal bundle (tectoreticular and tectospinal).

### *Descending tectofugal fibers*

Efferent fibers from the superior colliculus projecting downward in the brain stem appeared organized into three bundles (1) the lateral descending tectopontine fibers (uncrossed), (2) the intermediate tectoreticular fibers (mostly uncrossed) and (3) the medial descending predorsal bundle and tectospinal tract (crossed). The first and third tracts were discrete collections of fibers with specific courses within the brain stem, while the second fasciculus appeared to consist of a more diffuse fiber system with a local distribution.

*Tectopontine bundle.* Fibers of this group constituted the largest descending fasciculus and appeared to originate from all areas of the superior colliculus. Most of these fibers came from cells in the lower layers of the colliculus. Lesions confined to the more superficial layers of the superior colliculus produced degenera-

tion in a considerably smaller number of fibers in this tract. The largest group of these fibers passed ventrolaterally beneath the superior and the inferior colliculi and medial to the brachium of the inferior colliculus. A smaller number of fibers appeared to pass caudally immediately beneath the colliculi. A few fibers were noted to pass into the inferior colliculus from its ventral and lateral borders, but none of these appeared to penetrate this structure for any distance. At this level fibers were located dorsal and lateral to the nuclei of the lateral lemniscus, but no preterminal degeneration was seen within this nuclear group. From this position beneath the inferior colliculus, fibers of this bundle passed ventrally along the lateral border of the pons and entered the dorsolateral pontine nucleus. Preterminal degeneration was abundant about cells of this group, but not all cells were closely surrounded by degenerated fibers. Cells located in the dorsal medial part of the nucleus seemed to receive most of the fibers, though small fascicles of degenerated fibers frequently passed farther ventrally into the lateral pontine nucleus. Since fibers of this bundle arborized extensively about cells of the pontine nuclei and could not be traced to other locations, it was presumed that they terminated here.

Not all fibers of the lateral "tectopontine" bundle extended as far as the pontine nuclei. A diminution in the number of degenerated fibers was evident in sections from the level of the superior colliculus to the pons. Fibers were given off in the mesencephalic reticular formation; cells in this area were surrounded by degenerated fibers. Also, some fibers penetrated the magnocellular part of the medial geniculate body. Uncrossed tectopontine fibers were seen in all animals with lesions of the superior colliculus. In a few animals occasional degenerated fibers were present in the contralateral pontine nuclei.

*Tectoreticular bundle.* In cats with lesions restricted entirely to parts of the superior colliculus, it was possible to evaluate fiber projections to the homolateral reticular formation. These fibers, like those of the tectopontine bundle, appeared to originate largely from the deeper layers

of the superior colliculus. Fibers of this group were situated between those which swung ventromedially about the periaqueductal gray (predorsal bundle) and those which passed ventrolaterally (tectopontine fibers). Homolateral fibers were distributed largely to the dorsolateral mesencephalic reticular formation. A few fibers passed ventrally as far as the red nucleus, but only scattered single degenerated fibers were seen among the large cells of this structure. Most of the scattered degeneration within the homolateral reticular formation disappeared at upper pontine levels. No fibers of this group were observed to pass to the trochlear or abducens nuclei. Sections through the pons and medulla did not disclose many degenerated fibers in the reticular formation homolateral to the collicular lesions. On the side opposite to the lesion minimal degeneration was present in the dorsal mesencephalic tegmentum; degenerated fibers were restricted in distribution and appeared as a continuation of certain commissural fibers.

In animals with relatively large lesions, particularly those involving the ventral periaqueductal gray, extensive preterminal degeneration was seen in the homolateral reticular formation. These fibers were identified as a component of the central tegmental fasciculus and were noted to terminate in the ipsilateral inferior olivary complex (Walberg, '56).

*Predorsal bundle.* Fibers which formed the predorsal bundle, like the tectopontine and tectoreticular fibers, originated largely from the deeper layers of the superior colliculus. Fibers forming this descending tract curved ventromedially about the periaqueductal gray, passing ventral to the medial longitudinal fasciculus and the third nerve complex. In all animals, including those with lesions restricted entirely to the superior colliculus, it was possible to follow preterminal degeneration from this bundle into the interstitial nucleus of Cajal ('52, '55) and the nucleus of Darkschewitsch (1889). Degeneration in these nuclei was bilateral, and available evidence indicated that the contralateral nuclei received fibers via the commissure of the superior colliculus. In animals with restricted collicular lesions

the third nerve nuclear complex did not contain degenerated fibers. In animals with lesions extending beyond the superior colliculus preterminal degeneration was scattered in various parts of the oculomotor nuclei.

Below this level, fibers of the predorsal bundle all crossed the median raphé in the dorsal tegmental decussation, dorsal and rostral to the decussation of the brachium conjunctivum. Contralaterally these fibers formed a loosely organized descending fasciculus which, at lower levels, pierced the fibers of the brachium conjunctivum at a right angle. Below the level of the brachial decussation fibers of the predorsal bundle were oriented longitudinally along the lateral border of the superior central nucleus. This fiber bundle appeared more compact ventrally and was situated dorsomedially to the fibers of the descending limb of the brachium conjunctivum (Carpenter and Nova, '60). Although some fibers of this system appeared to occupy part of the area containing descending fibers of the brachium conjunctivum, the predorsal bundle was distinctly separate from the medial longitudinal fasciculus at this level.

In almost all cases degenerated preterminal fibers were observed in the lateral part of the superior central nucleus. Rostrally the number of fibers entering this nucleus was less than in the more caudal area. Maximum preterminal degeneration usually was seen in the ventral and caudal part of this nucleus, but even in this location no extensive arborization about cells was seen. In some animals a few degenerated fibers were seen in the dorso-medial part of the left reticulo-tegmental nucleus. Degenerated fibers in this nucleus were not seen in animals with lesions confined to the superior colliculus.

At the level of the trapezoid body degenerated fibers in the predorsal bundle began to be partially incorporated within the ventral part of the medial longitudinal fasciculus. There appeared to be a definite reduction in the number of fibers below this level. This reduction in the number of descending fibers appeared to be associated with the projection of small groups of fibers into the vicinity of large reticular neurons and the projection of

other fibers into the median raphé (i.e., inferior central nucleus). As fibers of this system descended into the medulla they became a more integral part of the medial longitudinal fasciculus, but were always located in the most ventral part. At various levels preterminal fibers were seen surrounding reticular neurons near the midline. Fibers of the predorsal bundle did not appear to surround closely the cells of the paramedian reticular nuclei, although an occasional cell seemed to have a few degenerated fibers in its vicinity.

At the caudal border of the medulla fibers of the predorsal bundle entered the spinal cord via the most ventral part of the ventral white column. In the spinal cord tectospinal fibers did not form a compact fasciculus, but were scattered in the ventral and lateral part of the ventral funiculus. Sections of spinal cord as far down as C-6 revealed preterminal degeneration, but it was usually not possible to outline precisely the limits of the tectospinal tract in transverse sections. Preterminal degeneration was found among anterior horn cells on the side opposite the lesion. Degenerated fibers entered the ventral horn from a ventral direction and appeared to be most concentrated in the intermediate zone at the base of the ventral horn. No preterminal degeneration was seen in the dorsal horn.

Preterminal degeneration within the spinal cord was greatest in the upper cervical segments. No preterminal degeneration was seen at the 8th cervical segment or in thoracic spinal segments.

#### *Ascending tectofugal fibers*

Efferent fibers from the superior colliculus projecting upward in the diencephalon appeared to be organized into three fiber bundles: (1) the dorsal ascending, (2) ventral ascending bundles (both of which left the lateral aspect of the superior colliculus by way of its brachium), and (3) the medial ascending bundle, which issued from the medial aspect of the superior colliculus through the medial portion of the brachium.

As mentioned above, a large bundle of tectofugal fibers passed laterally toward the brachium of the superior colliculus.

These fibers entered the brachium and then divided into two tracts. The largest division of these fibers, designated as the dorsal ascending tract, passed dorsolateral to the medial geniculate body and entered the medial part of the optic tract ventral to the lateral geniculate nucleus. The smaller division of these fibers, designated as the ventral ascending tract, curved around the lateral wall of the medial geniculate body, entered the medial part of the optic tract, and passed toward the optic chiasma.

*Dorsal ascending fibers.* Fibers of the dorsal ascending tract passed dorsomedially in the optic tract and were distributed to (1) the lateral part of the pretectum, (2) the supragenicular nucleus, (3) the caudal part of the pulvinar, and (4) the caudal part of the posterolateral nucleus. In these nuclei typical preterminal degeneration closely surrounded cells, suggesting that fibers probably terminated in these locations. No fibers of this division were observed to enter the dorsal or laminated portion of the lateral geniculate nucleus.

While the principal dorsal portion of the lateral geniculate nucleus was totally devoid of degeneration, some degenerated fibers were observed in the ventral portion of this structure (the pregeniculate nucleus).

*Ventral ascending fibers.* The relatively small number of fibers constituting this ascending division passed ventrally, partly in the dorsal part of the optic tract towards the optic chiasm. These fibers, clearly evident in the dorsal aspect of the chiasma, could be followed contralaterally, where they climbed in the medial part of the optic tract. While these fibers, constituting a tectal contribution to Guden's commissure, were partially situated within the hypothalamus, none of them appeared to terminate in this region. The terminal region of these fibers could not be determined from the available material.

In order to ascertain whether any of these optic tract fibers entered the optic nerves, longitudinal and transverse sections of the optic nerves were made in 6 cats. In 4 of these animals no degenerating fibers were seen; in two animals fibers with bead-like swellings were ob-

served, but the typical picture of axonal degeneration was lacking. With this evidence, the problem of the existence of centrifugal tecto-retinal fibers could not be resolved.

*Medial ascending fibers.* Fibers issuing from the medial aspect of the superior colliculus projected rostrally into the diencephalon as a small discrete bundle. As this fasciculus passed dorsolaterally, fibers were given off to (1) the pretectum, (2) the dorsomedial part of the supragenicular nucleus, (3) the dorsomedial aspect of the caudal portion of the posterolateral nucleus, and (4) the dorsomedial part of the caudal portion of the pulvinar. Some degenerated fibers appeared to enter also the caudal part of the dorsomedial nucleus. No fibers of this group could be followed into the habenular nuclei.

In animals with large lesions in the superior colliculus, particularly in which the lesions invaded the periaqueductal gray or dorsal tegmental structures, preterminal degeneration was also observed in the centromedian and parafascicular nuclei, in Forel's field H<sub>1</sub>, and in the ventral and lateral parts of the thalamic reticular nuclei. In animals with superficial or restricted lesions few if any degenerated fibers were present in these structures.

Diencephalic degeneration following collicular lesions was almost exclusively ipsilateral. Some degenerated fibers were observed in a few cases in the posterior commissure, in the contralateral nuclei of the posterior commissure, in the contralateral pretectum and centromedian nucleus.

#### DISCUSSION

The present investigation of the superior colliculus in the cat, based upon an improved technique for studying fiber degeneration, indicates that efferent fiber projections of this structure are more extensive than prior reports have shown. The principal contribution appears to be new data concerning (1) the tectoreticular fiber systems and (2) tectothalamic projections from this structure.

Descending fiber projections from the superior colliculus appear to be distributed largely to the brain stem reticular formation. These fibers are organized into two systems: (1) a diffuse uncrossed and

partially crossed fiber system with a local distribution in the mesencephalon and (2) a more compact crossed fasciculus which descends through the pons and medulla near the median raphe.

The most abundant tectoreticular fiber system appears to be distributed in the dorsal part of the upper mesencephalon. These fibers are bilateral, but are more abundant and cover a wider area on the side of the lesion. Fibers on the opposite side appear to cross almost entirely via the commissure of the superior colliculus. None of these fibers on either side extend ventrally into the red nucleus or substantia nigra. The ventral projection of uncrossed fibers is greater than for crossed fibers.

The exclusively crossed tectoreticular fibers form the predorsal bundle; more caudally projected fibers of this group enter the spinal cord and are designated as tectospinal fibers. Fibers with this course have been variously referred to as the *Vierhügelvorderstrangbahn* (German literature), the ventral longitudinal fasciculus (Collier and Buzzard, '01), the *praedorsales Längsbündel* (Tschermak, 1898), *faisceau longitudinal prédorsal* (Pavlow, '00), *le faisceau descendant de la calotte* (Cajal, 1896), and *le faisceau optique descendant* (van Gehuchten, '04). The existence of this tract and descriptions of its course were later confirmed by numerous investigators (Bechterew, 1897; Thomas, 1899; Redlich, 1899; Probst, '00; Lewandowsky, '04; De Lange, '10; Tsai, '25; Papez and Freeman, '30; Rasmussen, '22, '36; Marburg and Warner, '47; and Bürgi '57). General agreement exists concerning the origin and course of these fibers in the brain stem, but data concerning the nuclei upon which the fibers terminate show discrepancies.

The present investigation reveals that lesions restricted to the superior colliculus do not produce preterminal degeneration in the oculomotor nuclear complex. However, degenerated fibers can be traced into the nuclei of Darkschewitsch and the interstitial nuclei of Cajal. Fiber projections to these nuclei appear bilateral and suggest that crossed fibers probably reach the opposite side via the commissure of the superior colliculus. No descending

fibers of this system could be followed into the trochlear or abducens nuclei, or into any cranial nerve nucleus. It would seem that if any connections exist between the superior colliculus and the nuclei of the extraocular muscles, these connections are indirect and probably mediated by cells of the nuclei of Darkschewitsch and Cajal, a suggestion previously made by Szentágothai ('50). These results regarding the absence of tectal fiber projections to the third nerve nuclear complex agree with findings of more recent investigators (Papez and Freeman, '30; Rasmussen, '36; Marburg and Warner, '47; and Szentágothai, '50) but are at variance with some of the earlier descriptions (Held, 1890, 1892, 1893; Bechterew, 1897; Pavlow, '00; and Collier and Buzzard, '01).

The majority of descending fibers of the predorsal bundle appear to terminate upon neurons in the most medial part of the reticular formation. It was our impression that interlacing preterminal fibers about neurons in the reticular formation were most abundant in the pons. Some fibers of this descending system were observed to enter the superior and inferior central nuclei, with more fibers in the latter structure. Judging by the reduction in the number of fibers below pontine levels, approximately half of these fibers probably terminate in the pons. In the medulla fibers of this tract are incorporated in the ventral part of the medial longitudinal fasciculus. Very few fibers of this group appear to end in close relationship with cells of the paramedian reticular nuclei in the medulla, confirming data supplied by Brodal and Gogstad ('57).

Our data indicate that one of the principal descending fiber projections of the superior colliculus is into the brain stem reticular formation. In the mesencephalon tectofugal fibers are distributed bilaterally, with a homolateral preponderance. In the pons and medulla tectoreticular fibers are exclusively crossed, pass caudally in the predorsal bundle, and are given off to reticular neurons in a paramedian location. Findings reported here support the conclusion of Pearce ('53; also quoted by Jefferson, '58), and the published diagram (Jefferson, '58, p. 66) appears to show accurately the distribution

of these fibers. According to Jefferson, Pearce has demonstrated that stimulation of the superior colliculus in the cat under light anesthesia provokes typical EEG activation of the cerebral cortex, and occasionally an arousal response. His belief that visual activation of the cerebral cortex is mediated by tectoreticular fiber systems seems to be supported by his anatomical studies and those presented here.

The continuation of the predorsal bundle in the spinal cord is represented by tectospinal fibers. These fibers are few in number, scattered and found mostly in the lateral part of the ventral funiculus. In this material these fibers did not appear to form a discrete tract, but could be seen passing into the anterior horn. Degenerated fibers were most numerous at the base of the anterior horn in the zona intermedia. Descending fibers of this system projected caudally into the lower cervical spinal segments, but were not found at lower spinal levels. It was our impression that tectospinal fibers constitute a relatively small part of the predorsal bundle and represent a very minor spinal system.

The findings reported above are in essential agreement with the reports of Held (1892), Redlich (1899), Rasmussen ('36), Marburg and Warner ('47), and Bürgi ('57). Other investigators using the Marchi technique (Boyce, 1894; Tschermak, 1898; Collier and Buzzard, '01; and De Lange, '10) claim that tectospinal fibers descend below cervical segments. Most investigators agree that tectospinal fibers terminate among anterior horn cells (Redlich, 1899; Probst, '00; Rasdolsky, '23; Rasmussen, '36; Szentágothai-Schimert, '41).

There is almost universal agreement concerning the course and termination of tectopontine fibers. Although these fibers were first mentioned by Held (1890), a more complete description was made later by Muenzer and Wiener ('02). Available evidence indicates that tectopontine fibers originate only in the superior colliculus (Woollard and Harpman, '38), and terminate largely, if not exclusively, upon the dorsolateral pontine nuclei. Studies by Brodal and Jansen ('46) have demonstrated that the dorsolateral pontine nuclei project chiefly upon vermal cortex of the cerebellum and include the area in which

Snider ('50) has found evoked auditory and visual responses. It seems likely that some of the optic impulses may be transmitted to the cerebellar cortex via this system. No direct tectofugal fibers could be followed into any part of the cerebellum.

The present study appears to provide new data concerning diencephalic fiber projections of the superior colliculus. While the brachium of the superior colliculus has long been regarded as a primary afferent tract to the superior colliculus, it has not been recognized as containing any appreciable number of tectofugal fibers. Efferent fibers in the brachium are numerous and project laterally toward the lateral geniculate body. None of these fibers enter the dorsal or laminated part of the lateral geniculate body. However, a small number of fibers definitely project to the pars ventralis of the lateral geniculate body. This connection with the phylogenetically older part of the lateral geniculate suggests that some vestigial component of the tectogeniculate fiber system of lower mammals (Ariëns Kappers, Huber and Crosby, '36, p. 1073) probably remains even in higher forms. This very sharp separation of the more ancient tectal system from the more highly evolved and more recently developed geniculo-cortical system poses an interesting problem in comparative neurology.

Other ascending tectofugal fibers pass into the pars magnocellularis of the medial geniculate body, as defined by Rioch ('29). While it is not known whether this portion of the medial geniculate is phylogenetically older than the principal nucleus, it has been demonstrated that this nuclear group is not responsive to click stimuli (Rose and Woolsey, '49; Rose and Galambos, '52). The fact that this nucleus is not associated with the primary relay of auditory impulses suggests that it may in some ways be homologous to the pars ventralis of the lateral geniculate body.

A large number of ascending fibers from the superior colliculus were followed rostrally into the pretectum, the supragenicular nucleus, and to specific portions of the posterolateral nucleus and the pulvinar. Fibers entering the posterolateral nucleus were numerous caudally, but diminished rapidly in more rostral sections.

Degenerations within the pulvinar were confined to the caudal portions of this structure situated medial to the laminated part of the lateral geniculate body. Bucher and Brger ('50) and Brger ('57) have reported tectofugal fibers passing to the pretectum, the suprageniculate nucleus, the reticular nucleus, centromedian nucleus, and Forel's field H<sub>1</sub>, but fibers projecting to other thalamic nuclei have not been described previously, as far as we can determine. These diencephalic projections are entirely ipsilateral.

Lesions of the superior colliculus in the cat produce degenerated fibers which pass in the medial part of the optic tract, and to some extent in the ventral wall of the hypothalamus, in the direction of the optic chiasma. These fibers cross in the chiasma, re-emerge on the contralateral side and then climb upward in the optic tract and the wall of the hypothalamus. The termination of these fibers, which represent a tectal contribution to Gudden's commissure, could not be determined (cf., Magoun and Ranson, '42).

In view of the great significance that is being attached to the problem of centrifugal projection to the various sense organs in general (cf., Granit, '55a), and to the retina in particular (Cajal, 1894; Granit, '55b; Dodd, '56; and Livingston, '59), the suggestion of a projection from the superior colliculus to the retina is of great interest. The absence of axonal degeneration in the optic nerve of the majority of animals investigated and its doubtful presence in others do not permit a conclusion on this question.

No anatomical support for the existence of a tectohabenular tract (Marburg and Warner, '47) or a tecto-nigral tract (Rasmussen, '36; Marburg and Warner, '47) was provided by the present study.

#### SUMMARY AND CONCLUSIONS

A study was made of the efferent fiber projections of the superior colliculus in the cat. Twelve animals with unilateral collicular lesions were studied. Degeneration provoked by these lesions was studied in histological preparations stained according to the Nauta and Gyax technique. Tectofugal fibers were found to be distributed to specific portions of the brain

stem reticular formation, the spinal cord and differentially to parts of certain caudally located thalamic nuclei.

The following conclusions were drawn from this study:

1. Tectoreticular fibers are projected diffusely into the dorsal part of the upper mesencephalic reticular formation bilaterally. Ipsilateral tectoreticular fibers are more abundant and more widely distributed than contralateral fibers which cross in the commissure of the superior colliculus.

2. Fibers contained in the predorsal bundle originate predominantly in the lower layers of the superior colliculus, cross completely in the dorsal tegmental decussation, and are distributed mostly to nuclei in the pontine and medullary reticular formation near the midline; some fibers of this bundle appear to terminate in parts of the superior and inferior central nuclei.

3. Some collicular fibers appear to project bilaterally in the immediate vicinity of the nuclei of Darkschewitsch and the interstitial nuclei of Cajal, but degenerated fibers are absent in the nucleus of the third nerve.

4. Remaining fibers of the predorsal bundle become incorporated in the ventral part of the medial longitudinal fasciculus in the medulla and continue caudally into the spinal cord, forming a tectospinal tract.

5. Fibers of the tectospinal tract in the cat are located in the lateral part of the ventral funiculus, appear scattered in this area, and descend only into lower cervical levels. These fibers appear to terminate about anterior horn cells, particularly those at the base of the anterior horn (zona intermedia).

6. A prominent compact bundle of uncrossed tectopontine fibers passes caudally beneath the colliculi and ends in the area of the dorsolateral pontine nuclei.

7. Ascending tectofugal fibers project ipsilaterally to: (a) the pars ventralis of the lateral geniculate body, (b) the pars magnocellularis of the medial geniculate body, (c) the pretectum, (d) the suprageniculate nucleus, (e) the caudal portion of the posterolateral nucleus of the thalamus and (f) to the most caudal part of the



pulvinar situated medial to the laminated portion of the lateral geniculate body.

8. A few tectofugal fibers enter the medial aspect of the optic chiasm; none of these fibers appear to enter the optic nerve or project into the hypothalamus.

9. No fibers originating from the superior colliculus in the cat appear to project to: (a) any cranial nerve nucleus, (b) the substantia nigra, (c) the red nucleus, (d) the habenular nuclei or (e) the dorsal part of the lateral geniculate body.

Two hypotheses are presented:

1. The extensive system of tectoreticular fibers may participate in EEG cortical activation provoked by visual stimuli.

2. Tectopontine fibers may be specifically concerned with the transmission of visual impulses to localized areas of the cerebellar cortex.

#### LITERATURE CITED

- Ariëns Kappers, C. U., G. C. Huber and E. C. Crosby 1936 *The Comparative Anatomy of the Nervous System of Vertebrates, Including Man*, 2 vols. Macmillan, New York, vol 2, chap. VIII, pp. 1061-1100.
- Bechterew, W. von 1897 Ueber centrifugale, aus der Seh- und Vierhügelgegend ausgehende Rückenmarksbahnen. *Neurol. Centralbl.*, 16: 1074-1077.
- Boyce, R. 1894 A contribution to the study of (i) some of the decussation tracts of the mid- and inter-brain, and (ii) of the pyramidal system in the mesencephalon and bulb. *Proc. Roy. Soc., London*, 56: 305-306.
- Brodal, A., and A. C. Gogstad 1957 Afferent connexions of the paramedian reticular nucleus of the medulla oblongata in the cat. *Acta Anat.*, 30: 133-151.
- Brodal, A., and J. Jansen 1946 The pontocerebellar projection in the rabbit and cat. *Experimental investigations. J. Comp. Neur.*, 84: 31-118.
- Bucher, V. M., and S. M. Bürgi 1950 Some observations on the fiber connections of the di- and mesencephalon in the cat. I. Fiber connections of the tectum opticum. *Ibid.*, 93: 139-172.
- Bürgi, S. 1957 *Das Tectum Opticum. Seine Verbindungen bei der Katze und seine Bedeutung beim Menschen. Dtsch. Z. Nervenheilk.*, 176: 701-729.
- Cajal, S. Ramón Y. 1894 *Die Retina der Wirbeltiere*. Bergmann, Wiesbaden, pp. 111-112.
- 1896 Beitrag zum Studium der Medulla oblongata, des Kleinhirns und des Ursprungs der Gehirnnerven. Barth, Leipzig, pp. 26-32.
- 1952-1955 (1909-1911) *Histologie du système nerveux de l'homme et des vertébrés*, 2 vols. Consejo Superior de Investigaciones Científicas, Madrid, vol. 2, chap. IX, pp. 175-193.
- Carpenter, M. B., and H. R. Nova 1960 Descending division of the brachium conjunctivum in the cat. *J. Comp. Neur.*, 114: 295-305.
- Carpenter, M. B., and J. R. Whittier 1952 Study of methods for producing experimental lesions of the central nervous system with special reference to stereotaxic techniques. *Ibid.*, 97: 73-132.
- Collier, J., and F. Buzzard 1901 Descending mesencephalic tracts in cat, monkey and man; Monakow's bundle; the dorsal longitudinal bundle; the ventral longitudinal bundle; the ponto-spinal tracts, lateral and ventral; the vestibulo-spinal tract; the central tegmental tract (centrale Haubenbahn); descending fibres of the fillet. *Brain*, 24: 177-221.
- Crosby, E. C., and J. W. Henderson 1948 The mammalian midbrain and isthmus regions. II. Fiber connections of the superior colliculus. B. Pathways concerned in automatic eye movements. *J. Comp. Neur.*, 88: 53-92.
- Darkschewitsch, L. 1889 Ueber den oberen Kern des Nucleus oculomotorius. *Arch. Anat. Physiol., Anat. Abt.*, 107-116.
- De Lange, S. J. 1910 The descending tracts of the corpora quadrigemina. *Folia Neuro-biol.*, 3: 633-657.
- Dodd, E. 1956 Centrifugal impulses in rabbit's retina. *J. Neurophysiol.*, 19: 301-307.
- Granit, R. 1955a Receptors and sensory perception. Yale Univ. Press, New Haven, chap. 4, pp. 81-112.
- 1955b Centrifugal and antidromic effects on ganglion cells of retina. *J. Neurophysiol.*, 18: 388-411.
- Held, H. 1890 Der Ursprung des tiefen Markes der Vierhügelregion. *Neur. Centralbl.*, 9: 481-483.
- 1892 Ueber eine directe acustische Rindenbahn und den Ursprung des Vorderseitenstranges beim Menschen. *Arch. Anat., Physiol., Anat. Abt.*, 257-264.
- 1893 Die centrale Gehörleitung. *Ibid.*, 201-248.
- Hornet, T. 1933 Vergleichend-anatomische Untersuchungen über das Corpus geniculatum mediale (c.g.m.). *Arb. Neur. Inst., Wiener Univ.*, 35: 76-92.
- Huber, G. C., and E. C. Crosby 1933 A phylogenetic consideration of the optic tectum. *Proc. Nat. Acad. Sci. (U. S.)*, 19: 15-22.
- 1943 A comparison of the mammalian and reptilian tecta. *J. Comp. Neur.*, 78: 133-168.
- Jasper, H. H., and C. Ajmone-Marsan 1954 *A Stereotaxic Atlas of the Diencephalon of the Cat*. National Research Council of Canada, Ottawa, Canada.
- Jefferson, G. 1958 Discussion. In: Henry Ford Hospital International Symposium, Reticular Formation of the Brain. Little, Brown, Boston, pp. 65-68.
- Lewandowsky, M. 1904 Untersuchungen über die Leitungsbahnen des Truncus cerebri und ihren Zusammenhang mit denen der Medulla spinalis und des Cortex cerebri. *Neur. Arb.*, 1: 63-147.
- Livingston, R. B. 1959 Central control of receptors and sensory transmission systems.

- In: Handbook of Physiology, section 1, vol. 1, Neurophysiology. American Physiological Society, Washington, chap. 31, pp. 741-760.
- Magoun, H. W., and M. Ranson 1942 The supraoptic decussations in the cat and monkey. *J. Comp. Neur.*, 76: 435-459.
- Marburg, O., and F. J. Warner 1947 The pathways of the tectum (anterior colliculus) of the midbrain in cats. *J. Nerv. Ment. Dis.*, 106: 415-446.
- Münzer, E., and H. Wiener 1902 Das Zwischen- und Mittelhirn des Kaninchens und die Beziehungen dieser Teile zum übrigen Centralnervensystem, mit besonderer Berücksichtigung der Pyramidenbahn und Schleife. *Monatsch. Psychiat. Neur.*, 12: 241-271.
- Nauta, W. J. H., and P. A. Gyax 1954 Silver impregnation of degenerating axons in central nervous system. A modified technique. *Stain Tech.*, 29: 91-93.
- Nishikawa, Y. 1923 Experimentelle Untersuchungen über einige Bahnen des Hirnstammes des Kaninchens. *Arch. Neur. Inst., Wien. Univ.*, 24: 357-396.
- Papez, J. W., and G. L. Freeman 1930 Superior colliculi and their fiber connections in the rat. *J. Comp. Neur.*, 51: 409-439.
- Pavlov, M. 1900 Les voies descendantes des tubercules quadrijumeaux supérieurs, I-II. *Le Nevraxe*, 1: 57-75, 129-136.
- Pearce, G. W. 1953 Experimental studies on the descending tectal tracts of the cat with particular reference to the reticular formation of the brain stem. *V<sup>e</sup> Congr. Neur., Internat., Lisbon*, 2: 107.
- Polyak, S. 1957 The vertebrate visual system, H. Klüver, ed. University of Chicago Press, Chicago, chap. VI, pp. 288-389.
- Probst, M. 1900 Experimentelle Untersuchungen über die Schleifenendigung, die Haubenbahnen, das dorsale Längsbündel und die hintere Commissur. *Arch. Psychiat. Nervenkr.*, 33: 1-57.
- Rascholsky, J. 1923 Ueber die Endigung der extraspinalen Bewegungssysteme im Rückenmark. *Z. Ges. Neur. Psychiat.*, 86: 361-374.
- Rasmussen, A. T. 1922 Experimental demonstration of the entire course of four descending tracts by a single alcoholic injection in the mid-brain of the cat. *Proc. Soc. Exp. Biol. Med.*, 20: 104-107.
- 1936 Tractus tecto-spinalis in the cat. *J. Comp. Neur.*, 63: 501-525.
- Redlich, E. 1899 Beiträge zur Anatomie und Physiologie der motorischen Bahnen bei der Katze. *Monatschr. Psychiat. Neur.*, 5: 112-128, 192-206.
- Rioch, D. M. 1929 Studies on the diencephalon of carnivora. I. Nuclear configuration of the thalamus, epithalamus and hypothalamus of dog and cat. *J. Comp. Neur.*, 49: 1-120.
- Rose, J. E., and R. Galambos 1952 Microelectrode studies on medial geniculate body of cat. I. Thalamic region activated by click stimuli. *J. Neurophysiol.*, 15: 343-357.
- Rose, J. E., and C. N. Woolsey 1949 The relations of thalamic connections, cellular structure and evocable electrical activity in the auditory region of the cat. *J. Comp. Neur.*, 91: 441-466.
- Snider, R. S. 1950 Recent contributions to the anatomy and physiology of the cerebellum. *Arch. Neur. Psychiat.*, Chicago, 64: 196-219.
- Szentágothai-Schimert, J. 1941 Die Endigungsweise der absteigenden Rückenmarksbahnen. *Z. Anat. Entwgesch.*, 111: 322-330.
- Szentágothai, J. 1950 Recherches expérimentales sur les voies oculogyres. *Sem. Hôp. Paris*, 26: 2989-2995.
- Thomas, A. 1899 Étude sur quelques faisceaux descendantes de la moëlle. *J. Physiol. Path. Gen.*, 1: 47-61.
- Tsai, C. 1925 The descending tracts of the thalamus and mid-brain of the opossum, *Didelphia Virginiana*. *J. Comp. Neur.*, 39: 317-348.
- Tschermak, A. 1898 Ueber den centralen Verlauf der aufsteigenden Hinterstrangbahnen und deren Beziehungen zu den Bahnen im Vorderseitenstrang. *Arch. Anat. Physiol., Anat. Abt.*, 291.
- Tsuchida, U. 1906 Ueber die Ursprungskerne der Augenbewegungsnerven und über die mit diesen in Beziehung stehenden Bahnen im Mittel- und Zwischenhirn. *Arch. Hirnanat. Inst., Zürich*, 2: 1-205.
- Van Gehuchten, A. 1904 Connexions centrales du noyau de Deiters et des masses grises voisines. *Névraxe*, 6: 21-73.
- Walberg, F. 1956 Descending connections to the inferior olive. An experimental study in the cat. *J. Comp. Neur.*, 104: 77-173.
- Woollard, H. H., and J. A. Harpman 1938 The connections of the inferior colliculus and the dorsal nucleus of the lateral lemniscus. *J. Anat. London*, 74: 441-458.

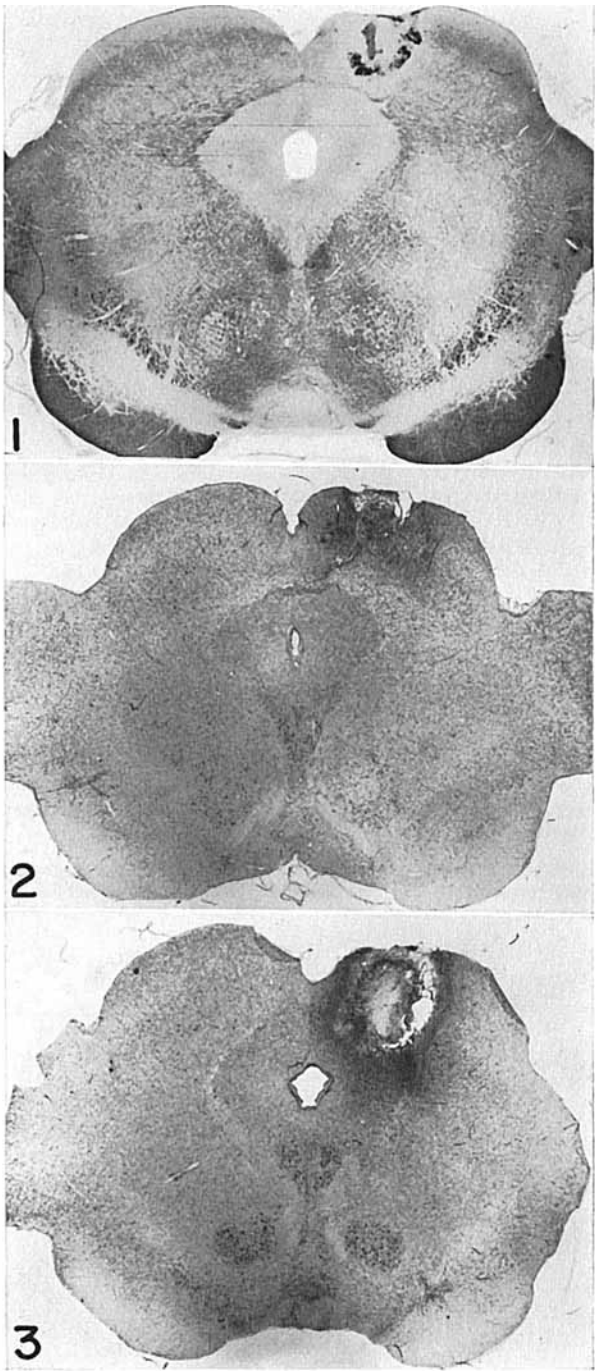
*Abbreviations to plates*

BSCl, brachium of superior colliculus, lateral part	MG, medial geniculate nucleus
BSCm, brachium of superior colliculus, medial part	MGMC, medial geniculate nucleus, pars magnocellularis
CG, central gray	MRF, mesencephalic reticular formation
CM, centromedian nucleus	NIII, nucleus of third nerve
DLPN, dorsolateral pontine nucleus	OT, optic tract
DTD, dorsal tegmental decussation	PDB, predorsal bundle
GUC, Gudden's commissure	PL, posterolateral nucleus
HB, habenular nuclei	PN, pontine nuclei
HT, hypothalamus	PT, pretectum
IC, inferior colliculus	Pul, pulvinar
IP, interpeduncular nucleus	RN, red nucleus
LG, lateral geniculate nucleus	SC, superior colliculus
LGD, lateral geniculate nucleus, pars dorsalis	SOD, fibers to supraoptic decussation
LGV, lateral geniculate nucleus, pars ventralis	TPT, tectopontine tract
	TST, tectospinal tract

## PLATE 1

### EXPLANATION OF FIGURES

- 1 Cat C-417. Photomicrograph showing restricted lesion in the right superior colliculus. Mahon.  $\times 6$ .
- 2 Cat C-442. Photomicrograph showing restricted lesion in the right superior colliculus. Nissl.  $\times 6$ .
- 3 Cat C-398. Photomicrograph illustrating extensive lesion in the right superior colliculus involving parts of the periaqueductal gray and dorsal tegmentum. Nissl.  $\times 6$ .

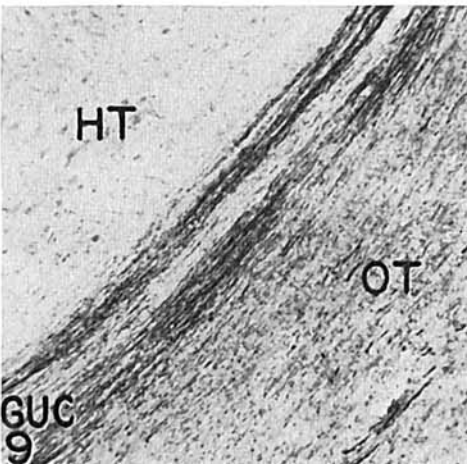
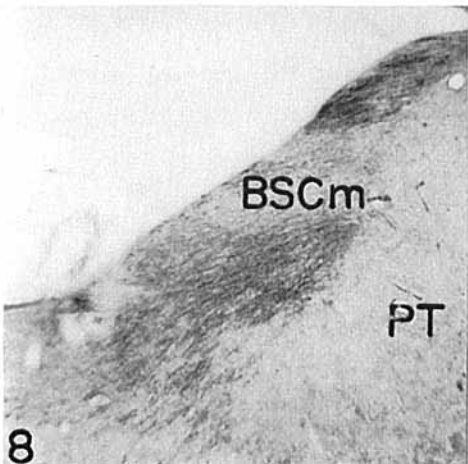

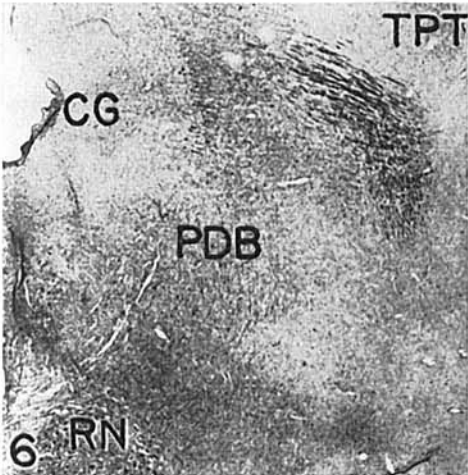
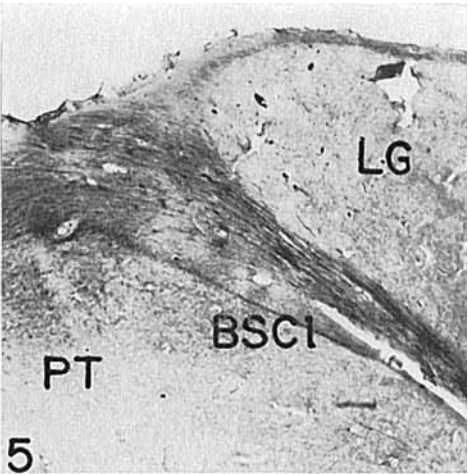
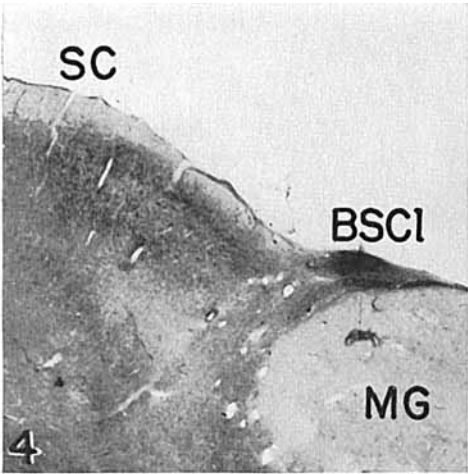


## PLATE 2

### EXPLANATION OF FIGURES

Low power photomicrographs showing axonal degeneration in some of the more important ascending and descending fiber tracts of the superior colliculus.

- 4 Cat C-398. Degenerated ascending tectofugal fibers passing through the lateral portion of the brachium of the superior colliculus. Nauta-Gygax.  $\times 12$ .
- 5 Cat C-387. Degenerated ascending tectofugal fibers in the medial part of the optic tract (on the medial wall of the lateral geniculate body) and in the brachium of the superior colliculus. Nauta-Gygax.  $\times 12$ .
- 6 Cat C-442. Degenerated fibers of the tectopontine tract and predorsal bundle. Nauta-Gygax.  $\times 12$ .
- 7 Cat C-398. Degenerated tectopontine fibers passing into the dorsolateral pontine nuclei. Nauta-Gygax.  $\times 75$ .
- 8 Cat C-442. Degenerated fibers in the medial part of the brachium of the superior colliculus in the pretectal region. Nauta-Gygax.  $\times 36$ .
- 9 Cat C-398. Degenerated fibers coursing in the medial aspect of the optic tract and within the ventral wall of the hypothalamus. Nauta-Gygax.  $\times 75$ .



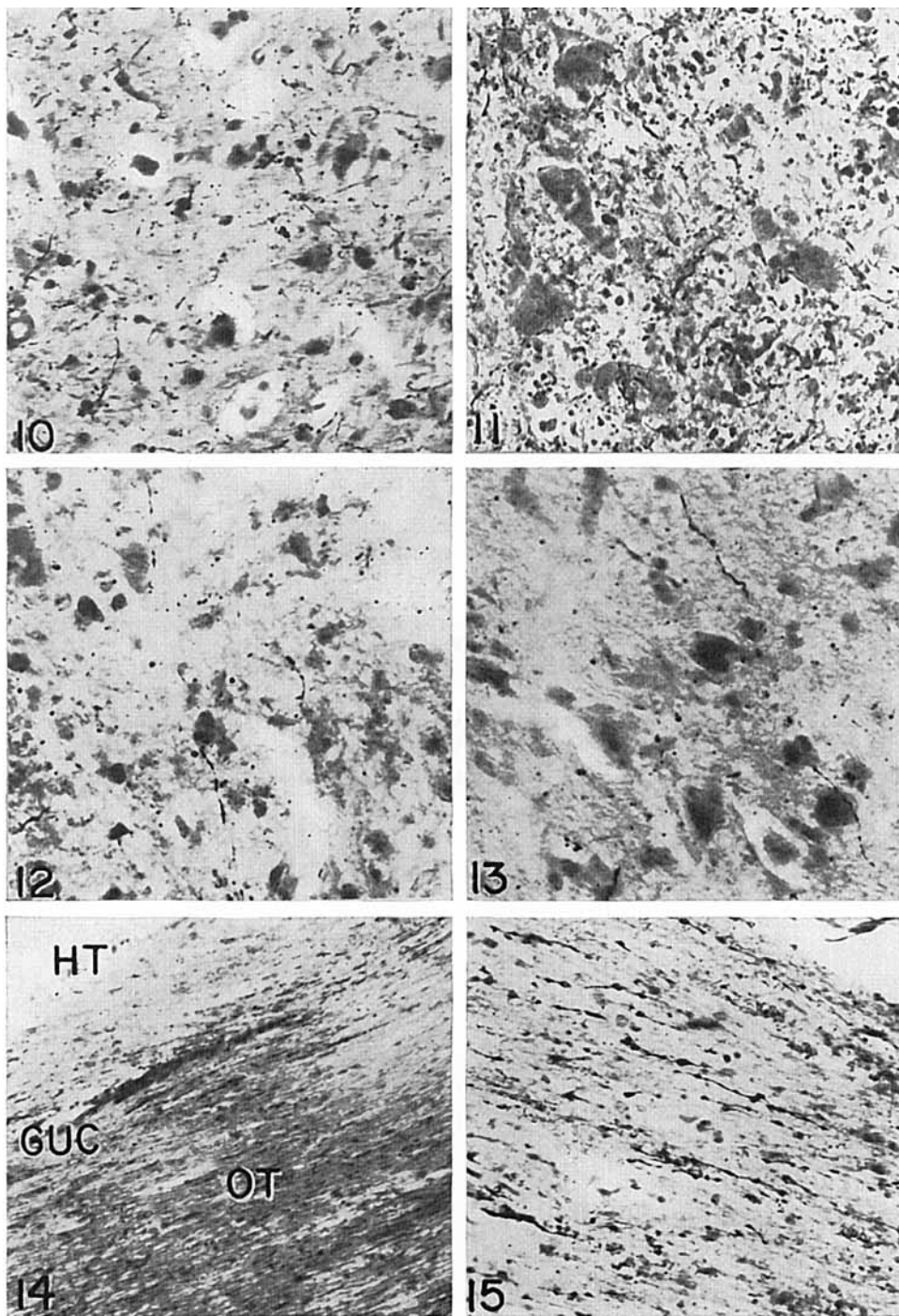
### PLATE 3

#### EXPLANATION OF FIGURES

High power photomicrographs illustrating ascending axonal and preterminal degeneration observed in various parts of the diencephalon following collicular lesions.

- 10 Cat C-442. Degenerated fibers present in the caudal part of the pulvinar. Nauta-Gygax.  $\times$  350.
- 11 Cat C-398. Pretectal region. Degenerated fibers surround cells in this area. Nauta-Gygax.  $\times$  550.
- 12 Cat C-397. Lateral geniculate nucleus, pars ventralis. A few degenerated fibers are present in this region. Nauta-Gygax.  $\times$  550.
- 13 Cat C-442. Medial geniculate body, pars magnocellularis. A few degenerated fibers present in this region. Nauta-Gygax.  $\times$  350.
- 14 Cat C-398. Degenerated fibers of Gudden's commissure coursing in the dorsal part of the optic tract and the ventral border of the hypothalamus. Nauta-Gygax.  $\times$  120.
- 15 Cat C-440. Right optic nerve. Fibers with beaded appearance, resembling degenerated fibers, are present in this region. Nauta-Gygax.  $\times$  350.



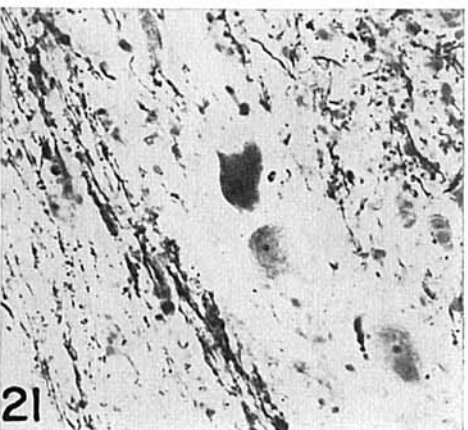
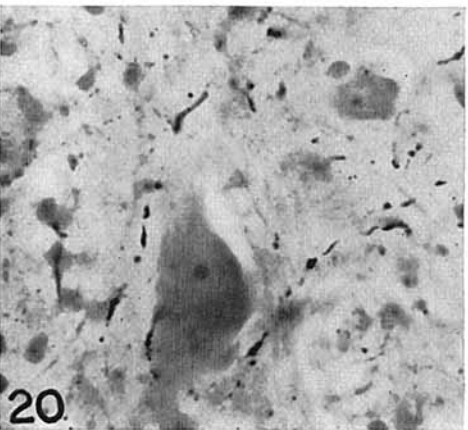
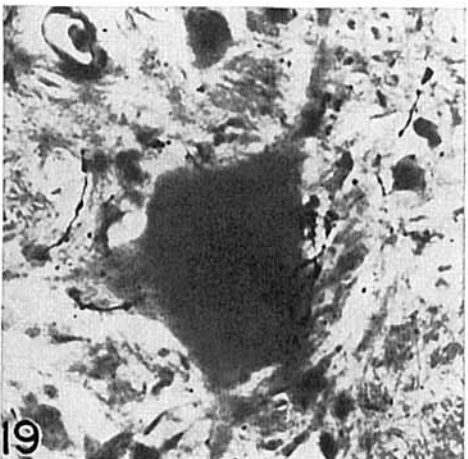

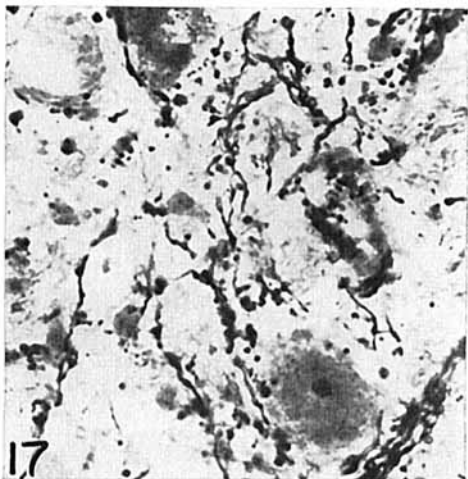
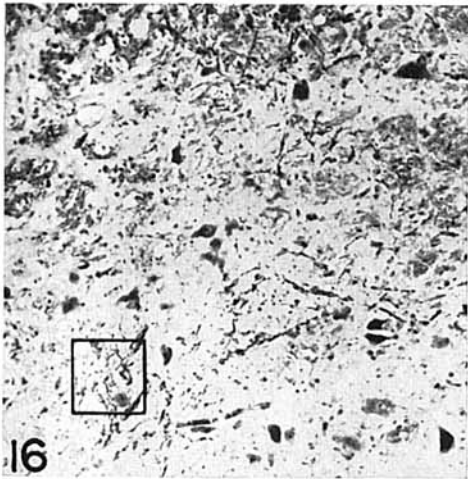


## PLATE 4

### EXPLANATION OF FIGURES

High power photomicrographs illustrating descending axonal and preterminal degeneration observed in pons and spinal cord following collicular lesions.

- 16-19 Cat C-442. Preterminal degeneration of fibers in the predorsal bundle in the contralateral pontine reticular formation. These illustrate types of fiber degeneration about reticular cells, including perineuronal arborization. Figure 17 represents higher magnification of area indicated in figure 16. Nauta-Gygax. Figure 16,  $\times 60$ ; figures 17-19,  $\times 350$ .
- 20 Cat C-442. Spinal cord, 4th cervical segment. Preterminal degenerated fibers in the vicinity of anterior horn cells. Nauta-Gygax.  $\times 350$ .
- 21 Cat C-398. Degenerated fibers passing into the dorsolateral pontine nucleus. Nauta-Gygax.  $\times 350$ .



## PLATE 5

### EXPLANATION OF FIGURE

- 22 Schematic drawings based in part upon the atlas of Jasper and Ajmone-Marsan ('54) showing distribution of axonal and preterminal degeneration in the upper brain stem and spinal cord following lesions in the right superior colliculus. The stripped areas indicate approximately the distribution of degenerated fibers. The solid black area indicates the lesion.

