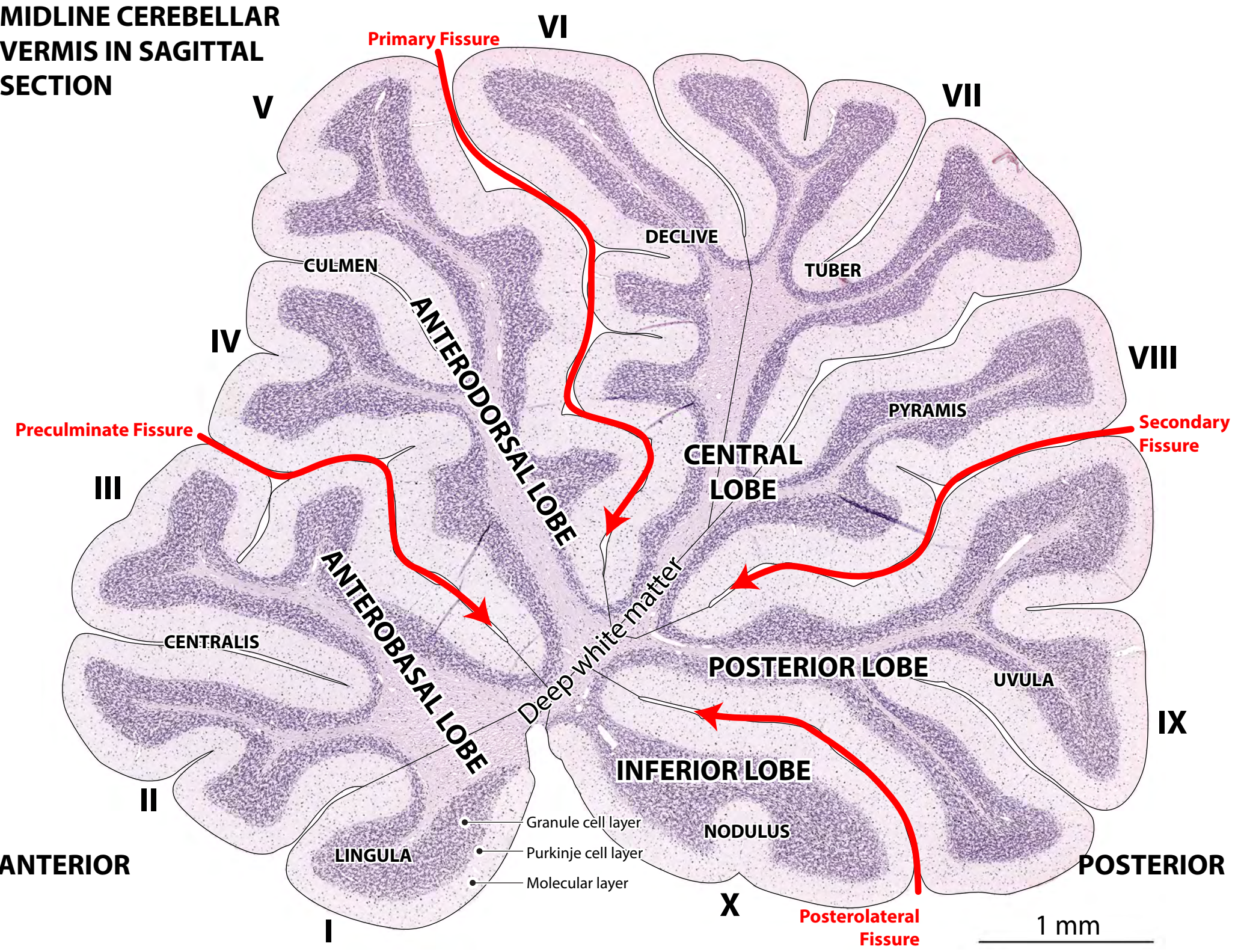


MIDLINE CEREBELLAR VERMIS IN SAGITTAL SECTION



Primary Fissure

VI

VII

V

DECLIVE

TUBER

CULMEN

ANTERODORSAL LOBE

PYRAMIS

VIII

Preculminate Fissure

Secondary Fissure

CENTRAL LOBE

III

Deep white matter

ANTEROBASAL LOBE

POSTERIOR LOBE

CENTRALIS

UVULA

IX

INFERIOR LOBE

NODULUS

LINGULA

- Granule cell layer
- Purkinje cell layer
- Molecular layer

ANTERIOR

POSTERIOR

Posterolateral Fissure

1 mm

I

X

II