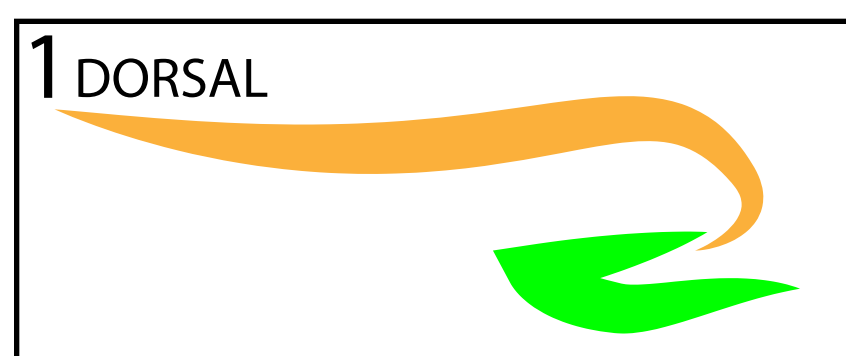
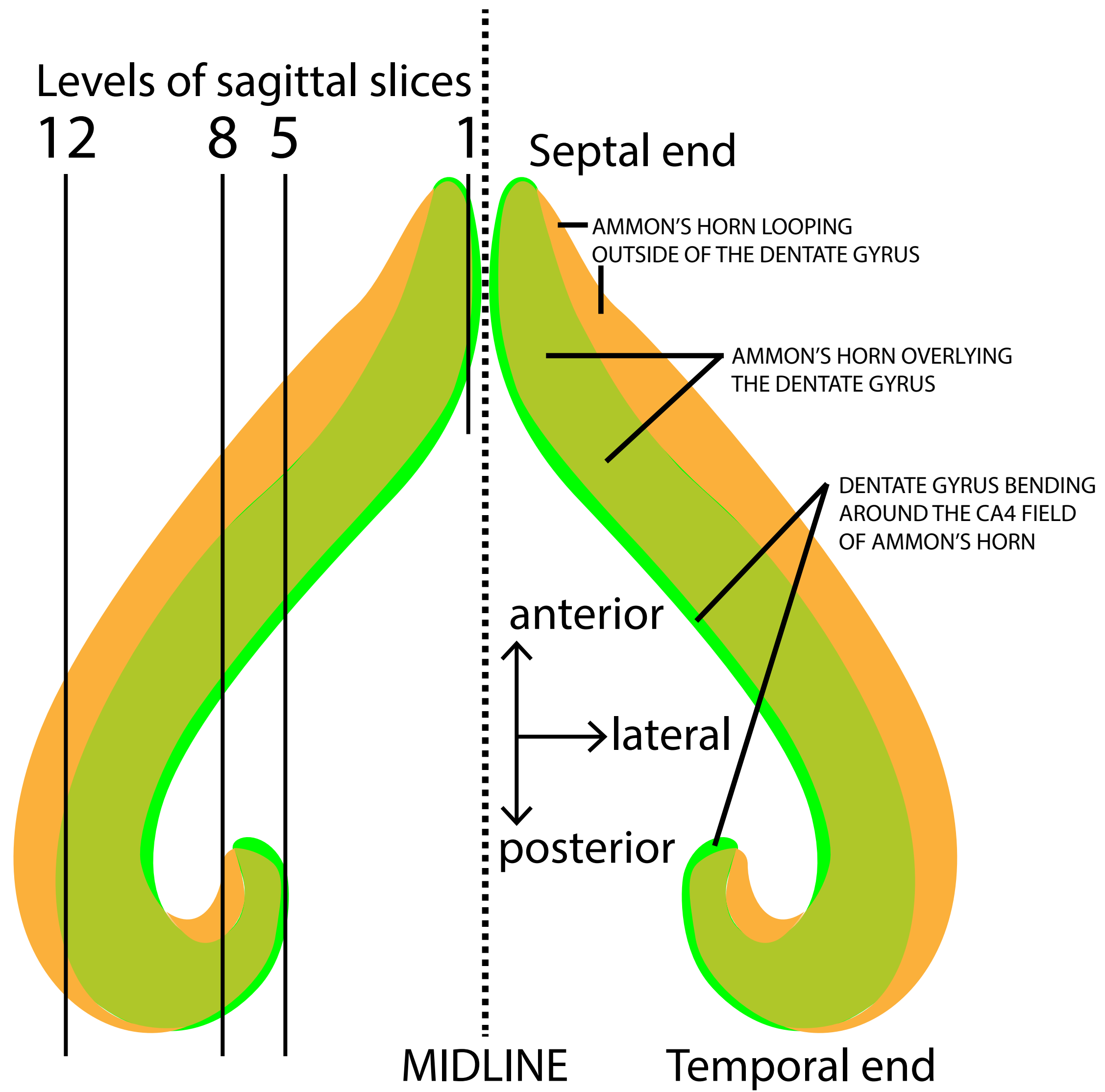


DIAGRAMMATIC TOP-DOWN VIEW OF THE RAT HIPPOCAMPUS



PROFILES OF AMMON'S HORN AND THE DENTATE GYRUS IN SAGITTAL SLICES

